

VALIDITY AND RELIABILITY OF DIGITAL PHOTOS AS A DIAGNOSTIC TOOL FOR DETERMINATION OF CARIES

Nasruddin MF¹, Mohamed Zohdi N¹, Roslan SA¹, and Nik Mohd Rosdy NMM².

¹Centre of Comprehensive Care Studies, Faculty of Dentistry, Universiti Teknologi MARA

²Centre of Oral & Maxillofacial Diagnostics & Medicine Studies, Faculty of Dentistry, Universiti Teknologi MARA

Correspondence:

Mohd Faiz bin Nasruddin,
Centre of Comprehensive Care Studies,
Faculty of Dentistry, Sungai Buloh Campus,
Universiti Teknologi MARA,
47000 Jalan Hospital, Selangor, Malaysia.
Email: drfaiz@uitm.edu.my

Abstract

Objectives: The impact of COVID-19 on dental care and the adoption of tele-dentistry for caries detection needs investigating. The pandemic led to the use of digital photography, including DSLR cameras and smartphones, for remote dental operations. Literature suggests that use of digital images was found to enhance caries detection sensitivity compared to visual examination. The study aims were 1) to compare the reliability of visual inspection and digital photographs for caries diagnosis among dental clinicians and 2) to compare diagnostic tools of determination of caries between full ICDAS codes and modified ICDAS codes utilization. **Methods:** The research involved 45 postgraduate dental students examining 45 extracted permanent teeth using full ICDAS scores and modified ICDAS scores in three phases (Full Visual ICDAS, Digital ICDAS and Combination of Visual and Digital ICDAS). Kappa scores, sensitivity, specificity and Area Under the Curve (AUC) readings between participants answers and benchmark answers were determined. **Results:** Statistical analysis revealed that introducing digital images reduced inter-rater agreement, however modified ICDAS codes utilization showed comparable results between visual and digital methods. Intra-rater agreement for visual and modified ICDAS was high, while digital images showed moderate agreement. Sensitivity for caries detection was around 93% for visual and digital methods, and specificity ranged from 67% to 80%. The AUC values indicated good performance (0.89) for both full and modified ICDAS with visual examination and lower values for digital examination (0.81-0.82). **Discussion:** Results were consistent with prior studies however this research highlights video/image efficacy, emphasizing validity, reliability, and improved clinician planning using modified ICDAS. **Conclusion:** Use of digital photographs for caries diagnosis were promising and the use of modified ICDAS codes were comparable to conventional use of full ICDAS codes. Overall, the study demonstrated the potential benefits of digital methods in dental caries diagnosis and tele-dentistry practices.

Keywords: Diagnosis, Digital Images, International Caries Detection Assessment System (ICDAS), Reliability and Validity.

Introduction

The COVID-19 pandemic has significantly impacted the healthcare system, particularly in fields like dentistry that require direct contact with patients. The World Health Organization (WHO) recently feared that this virus may become just another endemic virus in our communities and may never go away (1). To mitigate the risks of virus transmission, strict measures have been implemented globally, prompting the adoption of tele-dentistry as an alternative means of providing oral health care. This shift has led to the suspension of most routine dental

procedures, with only emergency dental services being performed. Tele-dentistry involves the use of information and communication technologies to remotely deliver oral health care (2). It relies on the utilization of photos or videos for information gathering, which are then transmitted from the patient to healthcare practitioners. Although studies have demonstrated tele-dentistry's value, physicians continue to fight against its deployment and are concerned about the credibility of findings when used (3, 4). Digital photography in dentistry has played a crucial role in enhancing diagnostic capabilities.

Advanced digital imaging allows for the creation of high-resolution images that can be easily shared, displayed, and transmitted without loss of quality.

The use of digital photography has proven valuable in various dental applications, including epidemiology, caries identification, and enamel disorders (5). It has been particularly beneficial in enhancing the sensitivity of caries detection compared to visual examination alone. Decayed Missing Filled Teeth scores acquired from examination using digital photography have been used to plan treatment needs, notably in rural regions where dentists are not accessible (6). In areas where access to traditional dental services is limited, digital photos obtained through tele-dentistry have been instrumental in planning treatment needs, especially in rural regions with limited dentist availability.

While Digital Single Lens Reflex (DSLR) cameras are recommended for dental photography, smartphones have emerged as convenient and accessible tools for capturing intraoral images (7). Smartphone photography has demonstrated effectiveness in oral screening and diagnosis, with research showing that virtual diagnoses based on smartphone images can be comparable to in-person assessments (8). The simplicity and efficacy of tele-dentistry, especially when using smartphones, have been highlighted in various studies. However, evidence of the use of mobile cameras in epidemiological dental testing is uncommon (9). This could be explained by uncertainty of accuracy of findings and quality of pictures produced by use of smartphone cameras.

Smartphones equipped with imaging technologies have proven to be user-friendly and accessible, making them a practical tool for remote dental monitoring. Studies have shown that patients can be successfully tracked using images and messaging apps, reducing the need for physical interaction (8). Furthermore, smartphone-based remote screening for dental caries has demonstrated high specificity and sensitivity, making it a viable alternative to traditional approaches (9).

The International Caries Detection and Assessment System (ICDAS) plays a crucial role in identifying dental caries at different stages. The ICDAS criteria provide a standardized method for interpreting visual signs of caries, offering high reproducibility and clinically good specificity and sensitivity. The ICDAS codes for coronal caries varies from 0-6 depending on

the degree of the lesions which are sound, first visual change in enamel, distinct visual change in enamel, localized enamel breakdown, an underlying dark shadow from dentine, distinct cavity with visible dentin and extensive distinct cavity with visible dentin respectively (10, 11). The recent simplification of ICDAS codes by the International Caries Classification and Management System Group (ICCMS) has further streamlined the assessment process (12).

In comparison to traditional diagnostic methods, including fibre-optic transillumination, quantitative light-induced fluorescence, and near-infrared light transillumination, visual examination and ICDAS detection have shown similar accuracy relative to histological methods (13). Visual examination is considered a straightforward, low-technology, and quick-to-implement tool for caries diagnosis, making it suitable for dental public health (13).

Despite the availability of other diagnostic methods such as radiographs, their use is limited due to concerns about ionizing radiation exposure and the challenges in distinguishing between different dental lesions (5). The limitations of more advanced methods, such as digital imaging fibre-optic transillumination, further emphasize the practicality and efficiency of visual examination and ICDAS detection in dental practice. In conclusion, the integration of tele-dentistry, particularly using smartphones for digital photography, has proven to be a valuable solution in the face of the COVID-19 pandemic. The combination of remote screening, visual examination, and ICDAS detection offers an effective and efficient approach to oral health care, ensuring continuity in dental services even in challenging circumstances.

When compared to traditional visual examination methods, DSLR and smartphone are now possible remote-examine tele-dentistry methods that lead to improved patient satisfaction and shorter chair-side time. Few clinical studies have been conducted to assess the validity of employing DSLR and smartphone cameras with approximate true colours for caries screening. Scientific evidence that these digital cameras are viable for screening may change dental practises' strategic plans, leading to greater acceptance and wider use of tele-dentistry. The null hypothesis is that using digital images with different apparatus has no significant difference in terms of ICDAS determination. The study's main goal is to compare the reliability of visual inspection vs digital photographs as a technique of caries diagnosis among

postgraduate dental students at UiTM Sungai Buloh's Faculty of Dentistry. A secondary objective was to compare diagnostic tools of determination of caries between full ICDAS codes and modified ICDAS codes (Based on the recent changes by the ICCMS group) utilization.

Materials and Methods

Sample collection

This study is a prospective laboratory study comparing two different approaches of ICDAS determination. Ethical clearance was given by the Research committee of Universiti Teknologi MARA and consent forms for participants were all distributed. Only signed consented participants were selected. The study framework is displayed in Figure 1. The sample size of this study was decided based on the power sampling calculation of 80%, effect size of 0.25 and standard error of 5%. 36 participants (Convenient sampling of dental clinicians undergoing ICDAS calibration) were required for this study to give a statistical meaning result for the proposed study.

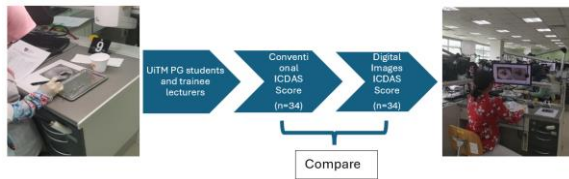


Figure 1: Framework of study

Extraoral conventional ICDAS score versus use of dental images

Forty-five (n=45) dental clinicians (comprising of postgraduate students, dental lecturers, and dental officers) were involved in this research at the Faculty of Dentistry, UiTM Sungai Buloh. The participants were chosen because they were experienced dentists with sufficient experience in categorising caries, which would reduce errors if novice dentists or undergraduate students were utilised. The research began using forty-five extracted permanent teeth representing ICDAS scores between 0 and 6. These teeth were stored in 0.1% thymol solution at 4°C. The teeth were cleaned and polished with pumice using a low-speed prophylaxis brush, then roots were embedded in a self-cure acrylic resin block. The blocks were labelled by number at the base and the surface of teeth were photographed and marked on the photograph with an arrow. Then, this study was carried out in three phases. For phase 1, the

participants were given 52 questions based on the 45 teeth for the ICDAS status to be scored. Some teeth had two cavities that required to be scored, such as mesial and distal caries. The participants visually examined the marked site on surfaces of the prepared teeth under light illumination. The teeth were kept hydrated by keeping their teeth in a cup of water.

After 2 weeks, the same 45 dental clinicians continued for Phase 2. Participants needed to score the first 22 extracted permanent teeth by visual examination and after 15 minutes, the remainder of the 45(n=23) extracted permanent teeth were scored using digital images taken by DSLR on computer. Phase 3 were conducted at 2 weeks interval. Again, the same 45 dental clinicians scored all the 45 teeth this time using only digital images taken with the DSLR via a computer monitor.

A single individual trained to operate a DSLR camera with no magnification but a macrolens with a ring light attached to a black and white backdrop took two photographs each tooth. The participants were shown both photographs at the same time. The data collected were analysed with statistical software (SPSS version 20.0) using Kappa scores to compare frequencies of accurate responses of caries detection between first and second examination (Phase 1 and 2) with national benchmark group (NBG) answers for ICDAS and through images of teeth (Phase 2 and Phase 3). The NBG was a group of restorative specialists selected by the Malaysian government to conduct calibrations with existing dentists in Malaysia in preparation for ICDAS implementation (14). According to the Landis and Koch classification, kappa values and bias index were measured by intra- and inter-examiner reproducibility to determine the absolute value of the difference between frequencies in the disagreement cells divided by the total number of ratings (15).

Results were reported as minimum and maximum value with mean kappa values pooled to compare between the different groups via paired sample t-test (16). The results' sensitivity and specificity would also be presented, with AUC readings and accuracy results. The AUC curve depicts the area under the Receiver Operator Characteristics (ROC) curve, and AUC stands for Area Under the Curve. It assesses the binary classification model's overall performance. Because both True Positive Rate (TPR) and False Positive Rate (FPR) range from 0 to 1, the area will

always be between 0 and 1, and a higher AUC value indicates better model performance. The main goal is to maximise this area so that we have the highest TPR and the lowest FPR at the stated threshold. The AUC quantifies the likelihood that the model would award a randomly selected positive case a higher projected probability than a randomly selected negative instance. Accuracy of each group will then be determined by use of a mathematical formula (17):

Accuracy: overall probability that a patient is correctly classified

$$= \text{Sensitivity} \times \text{Prevalence} + \text{Specificity} \times (1 - \text{Prevalence})$$

Results

Inter-rater agreement

Results are displayed in Figure 2. Minimum and maximum interrater agreement of Kappa scores using conventional method of visual ICDAS scoring through full ICDAS codes with respect towards the NBG data were 0.59 and 0.83 respectively with mean (SD) of pooled kappa scores of 0.71(0.04). When modified ICDAS codes were used, results were as follow; Min: 0.67, Max: 0.88, Mean (SD): 0.78(0.04).

Min: 0.31, Max: 0.8, Mean (SD): 0.69(0.05) were the results for interrater agreement utilising digital photos to assess ICDAS using full ICDAS codes. When the modified ICDAS codes were used, the minimum, maximum, and mean (SD) interrater agreement results were 0.18, 0.85, and 0.69(0.08), respectively. Paired sample t-test indicated statistically significant differences when compare were done between visual ICDAS and use of digital images ($p < 0.01$). When modified ICDAS score were used, the results between visual and use of digital images were comparable ($p = 0.05$).

Intra-rater agreement

Results are displayed in Figure 2. Upon utilising the conventional technique, the lowest and highest intra-rater agreement amongst doctors were 0.68 and 1. The mean (standard deviation) was reported to be 0.84(0.06). Using the modified ICDAS score, the values for min, max, and mean (SD) were 0.65, 1 and 0.83(0.07), respectively. The use of digital images to determine ICDAS score yielded findings of min: 0.41, max: 0.92, and mean (SD) of 0.72(0.09). While the modified ICDAS score for min, max, and mean (SD) were 0.51, 0.96, and 0.74(0.08), respectively. The

findings of the paired sample t-test comparing conventional and image usage were statistically significant ($p < 0.01$). When the same tests were run using a modified ICDAS score, the results were also significantly different ($p < 0.01$).

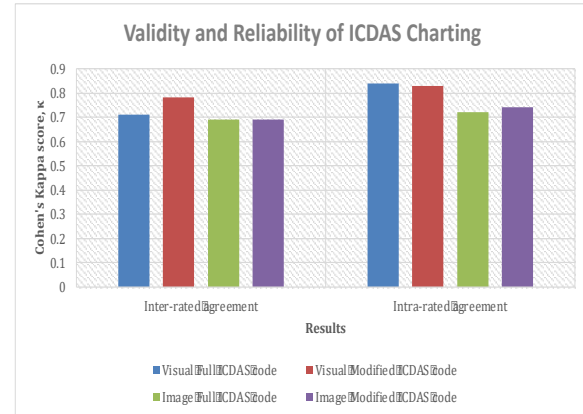


Figure 2: Inter- and intra- rated agreement between ICDAS answers of participants with benchmark answers from National Benchmark Group (NBG)

Sensitivity and specificity

Results were reported in Table 1. The mean average sensitivity reading while using traditional ICDAS for caries detection was 93.82%. The mean sensitivity was reported to be 93.18% when the modified ICDAS was employed. Specificity was 80.33% for full ICDAS code usage and 80.11% for modified ICDAS. When the Area under the Curve (AUC) was calculated, the findings for full codes vs modified ICDAS were both 0.89. The accuracy result was reported to be 89.15% for the full ICDAS code approach and 88.57% for the modified ICDAS method. The sensitivity of caries determination using digital photographs was 93.18% for complete ICDAS code utilisation and 93.29% for modified ICDAS code usage. Specificity was just 67.33% and 66.39%, with AUC readings of 0.82 and 0.81, respectively. The accuracy rate for complete ICDAS code use was 84.23%, and 83.98% for modified ICDAS code use.

Discussion

This study demonstrates that digital photos captured using digital cameras provide a viable method of remote screening for dental caries. Despite a scarcity of studies on the use of a smartphone camera in dental screening, our findings indicate the tele dentistry approach's ability to diagnose caries from a picture with acceptable moderate to high diagnostic

Table 1: Sensitivity, Specificity, AUC and Accuracy of methods determining Full ICDAS and Modified ICDAS

	Sensitivity (%)	Specificity (%)	Area under Curve (AUC)	Accuracy (%)
Visual Full ICDAS	93.82(95%CI: 76.14-97.4)	80.33(95%: 51.63-91)	0.89(95%CI: 0.75-0.93)	89.15(95%CI: 73.4-94.9)
Visual Modified ICDAS	93.18(95%CI: 77.5-97.9)	80.11(95%CI: 53.5-90.85)	0.89(95%CI: 0.7-0.91)	88.57(95%CI: 74.8-94)
Image Full ICDAS	93.18(95%CI: 77.8-94.83)	67.33(95%CI: 46.4-85.3)	0.82(95%CI: 0.65-0.89)	84.23(95%CI: 71.5-92.3)
Image Modified ICDAS	93.29(95%CI: 85-98.28)	66.39(95%CI: 50.08-89.6)	0.81(95%CI: 0.65-0.89)	83.98(95%CI: 70.78-92.84)

validity and reliability. It is widely documented that neither the photographic method nor the direct visual examination approach can detect interproximal or early caries lesions without radiographic assessment (18–20). The lack of tactile feeling, as well as the conversion of 3D objects into 2D visuals, and lighting complications further reduce the suitable conditions for diagnosing caries. The method of obtaining digital photographs has limits in terms of capturing all tooth surfaces, particularly posterior teeth. To avoid these constraints, we charted in two systems: Full ICDAS codes and modified ICDAS codes. The modified ICDAS was established to reduce the conventional ICDAS to a less detailed categorization. As a result, the focus of this study was on determining the dependability of using digital photos as a method for caries detection at the screening level.

The analysis demonstrated a moderate degree of inter-agreement reliability for visual and digital pictures, as well as intra-agreement reliability for image utilization in both full ICDAS codes and modified ICDAS charting systems. However, it indicated strong agreement in intra-rater reliability for both techniques of visual ICDAS use. This displays the consistency and reliability of findings when using visual ICDAS. The results show that using photographs to identify caries does not enhance clinical visual findings, and that visual findings are superior.

Despite the fact that the results when comparing visual and digital images with full ICDAS codes were statistically different, the diagnostic acceptability in clinical settings remained within moderate agreement, indicating that the results were still clinically valid (21). The findings were identical when modified ICDAS were utilised for intra-rater agreement, indicating that modified ICDAS should be used in conjunction with traditional visual ICDAS

determination or the use of photographs to aid in caries classification.

The sensitivity and specificity to detect caries were greater than in earlier investigations (18, 19). This might be due to the low quality of cameras utilised at the time of the investigation. This is to be expected as digital camera technology continues to advance. Morosini et al. (22) reported a greater sensitivity and specificity values in 2014, however the sensitivity and specificity values were even higher (73/98%) in a 2018 study conducted by Alabdullah and Daniel (4). Nonetheless, the high results obtained may be due to the utilisation of a standard laboratory-controlled environment in which clinical conditions intraorally may alter the findings obtained. However, the method's high AUC for both pictures and visual ICDAS classification makes it worth investigating.

From a practical aspect, it is appropriate to take advantage of technological advancements as well as increased global connectivity and pick alternatives such as DSLR and smartphone cameras to make dental care services more accessible in terms of awareness or even an alarm mechanism for patients to seek care. It might also be utilised as a screening tool for treatment and resource plannings by schools and the healthcare administration team.

Although using digital pictures to determine caries status has advantages, it also has limits. Because this study used a removed tooth, important variables such as saliva might interfere with the collecting of findings. There is currently no process in intraoral photography for standardising images that may be used for caries assessment, particularly if the image was taken by a layperson for professional use. Nevertheless, more research is required to determine the validity and reliability of images used for caries

determination in clinical settings to see the consequences of outcomes. Further research such as randomized control trials is suggested.

Conclusion

ICDAS assessments based on visual and digital images were valid, reliable, and comparable among postgraduate dental clinicians of UiTM Faculty of Dentistry and the use of modified ICDAS codes were comparable to conventional use of full ICDAS codes. As a screening tool, the study demonstrated the potential benefits of digital methods in dental caries diagnosis and tele-dentistry practices.

Acknowledgement

We acknowledge the faculty of dentistry of UiTM students and staff especially the ICDAS committee of UiTM in help during data collection for this paper.

Competing interests

The authors declare that they have no competing interests in fabrication of this article.

Ethical Clearance

We obtained approval from the Research committee of Universiti Teknologi MARA, registered under REC/08/2021 (MR/681).

Financial support

No funding was received for this work.

References

- Phillips N. The coronavirus is here to stay - here's what that means. *Nature*. 2021; 590(7846):382–384.
- Mariño R, Ghanim A. Definition of Teledentistry BT - e-Health Care in Dentistry and Oral Medicine: A Clinician's Guide. In: Giraudeau N, editor. Cham: Springer International Publishing; 2018. p: 3-14.
- AlShaya MS, Assery MK, Pani SC. Reliability of mobile phone teledentistry in dental diagnosis and treatment planning in mixed dentition. *J Telemed Telecare*. 2020; 26(1–2):45–52.
- Alabdullah JH, Daniel SJ. A Systematic Review on the Validity of Teledentistry. *Telemed J e-health Off J Am Telemed Assoc*. 2018; 24(8):639–648.
- Bottenberg P, Jacquet W, Behrens C, Stachniss V, Jablonski-Momeni A. Comparison of occlusal caries detection using the ICDAS criteria on extracted teeth or their photographs. *BMC Oral Health*. 2016; 16(1):1–8.
- Carvalho RN de, Letieri A dos S, Vieira TI, Santos TMP dos, Lopes RT, Neves A de A, et al. Accuracy of visual and image-based ICDAS criteria compared with a micro-CT gold standard for caries detection on occlusal surfaces. *Braz Oral Res*. 2018; 32:e60.
- Duong DL, Kabir MH, Kuo RF. Automated caries detection with smartphone color photography using machine learning. *Health Informatics J*. 2021; 27(2):14604582211007530.
- Steinmeier S, Wiedemeier D, Hämmerle CHF, Mühlemann S. Accuracy of remote diagnoses using intraoral scans captured in approximate true color: a pilot and validation study in teledentistry. *BMC Oral Health*. 2020; 20(1):266.
- Estai M, Kanagasingam Y, Huang B, Shiikha J, Kruger E, Bunt S, et al. Comparison of a Smartphone-Based Photographic Method with Face-to-Face Caries Assessment: A Mobile Teledentistry Model. *Telemed J e-health Off J Am Telemed Assoc*. 2017; 23(5):435–440.
- Gugnani N, Pandit I, Nikhil S, Monika G, Megha S. International Caries Detection and Assessment System (ICDAS): A New Concept. *Int J Clin Pediatr Dent*. 2011; 4:93–100.
- Topping GVA, Pitts NB. Clinical visual caries detection. *Monogr Oral Sci*. 2009; 21:15–41.
- ICCMS. ICDAS [Internet]. 2022. Available from: <https://iccms-web.com/content/icdas>. Accessed 31 Mar 2022
- Twetman S. Visual Inspection Displays Good Accuracy for Detecting Caries Lesions. *J Evid Based Dent Pract*. 2015; 15(4):182–184.
- Zohdi NM, Nasruddin MF, Sanusi MA. Performance of dental undergraduate students using International Caries Detection and Assessment system (ICDAS). *Compend Oral Sci*. 2020; 7(2):13-20.
- Landis JR, Koch GG. An Application of Hierarchical Kappa-type Statistics in the Assessment of Majority Agreement among Multiple Observers. *Biometrics*. 1977; 33(2):363–374.
- De Vries H, Elliott MN, Kanouse DE, Teleki SS. Using pooled kappa to summarize interrater agreement across many items. *Field methods*. 2008; 20(3):272–282.
- Zhou X-H, Obuchowski NA, McClish DK. Measures of Diagnostic Accuracy. In: *Statistical Methods in Diagnostic Medicine*. 2011. p: 13–55.
- Boye U, Pretty IA, Tickle M, Walsh T. Comparison of caries detection methods using varying

- numbers of intra-oral digital photographs with visual examination for epidemiology in children. *BMC Oral Health*. 2013; 13(1):1–11.
19. Boye U, Walsh T, Pretty IA, Tickle M. Comparison of photographic and visual assessment of occlusal caries with histology as the reference standard. *BMC Oral Health*. 2012; 12(1):1-7.
 20. Ortiz MIG, de Melo Alencar C, De Paula BLF, Magno MB, Maia LC, Silva CM. Accuracy of near-infrared light transillumination (NILT) compared to bitewing radiograph for detection of interproximal caries in the permanent dentition: A systematic review and meta-analysis. *J Dent*. 2020; 98:103351.
 21. Mary L McHugh. Interrater reliability: the kappa statistic. *Biochem Med*. 2012; 22(3):276–282.
 22. Morosini I de AC, de Oliveira DC, Ferreira F de M, Fraiz FC, Torres-Pereira CC. Performance of distant diagnosis of dental caries by teledentistry in juvenile offenders. *Telemed J e-health Off J Am Telemed Assoc*. 2014; 20(6):584–589.